

The International Classification of Retinopathy of Prematurity Revisited

*An International Committee for the Classification of Retinopathy of Prematurity**

The International Classification of Retinopathy of Prematurity (ICROP) was published in 2 parts, the first in 1984 and later expanded in 1987. It was a consensus statement of an international group of retinopathy of prematurity experts. The original classification has facilitated the development of large multicenter clinical treatment trials and furthered our understanding of this potentially blinding disorder. With improved imaging techniques in the nursery, we are able to offer a more quantitative approach to some of the characteristics described in the ICROP. An international group of pediatric ophthalmologists and retinal specialists has developed a consensus document that revises some aspects of ICROP. Few modifications were felt to be needed. The aspects that differ from the original classification include introduction of (1) the concept of a more virulent form of retinopathy observed in the tiniest babies (aggressive, posterior ROP), (2) a description of an intermediate level of plus disease (pre-plus) between normal posterior pole vessels and frank plus disease, and (3) a practical clinical tool for estimating the extent of zone I.

Arch Ophthalmol. 2005;123:991-999

The purpose of this article is to update the International Classification of Retinopathy of Prematurity (ICROP) using the evidence base that has accumulated since its first publication in 1984.¹ This document is the consensus of a group of 15 ophthalmologists from 6 countries, several of whom were members of the original ICROP committees from the early 1980s and all of whom have extensive clinical experience with this disorder. The original ICROP, described first in a 1984 publication¹ and expanded in 1987,² has provided a basis on which numerous treatment trials and observational studies of this potentially devastating disorder could be undertaken. The original ICROP dealt with the early phases of the disorder and was based on several key observations essential in describing the retinopathy. These include (1) the location of retinal involvement by zone, (2) the extent of retinal involvement

by clock hour, (3) the stage or severity of retinopathy at the junction of the vascularized and avascular retina, and (4) the presence or absence of dilated and tortuous posterior pole vessels (plus disease). The revision proposed herein has adhered to the original descriptive nature of the disease, and the committee has not attempted to explain the mechanism of the disease. However, improved retinal imaging techniques allow capturing images of a quality that was unimagined at the time of the initial classification and, thus, the developing retinopathy can be examined by several observers without endangering the tiny infant.

This present article combines both the original ICROP system and the additional changes that our committee recommends. The changes and additions have been integrated into a single document for the first time to provide the reader with a single source for the classification of this disease. The clarifications and changes recommended by the committee include the following:

Financial Disclosure: None.

*A list of the members of an International Committee for the Classification of Retinopathy of Prematurity appears on page 997.

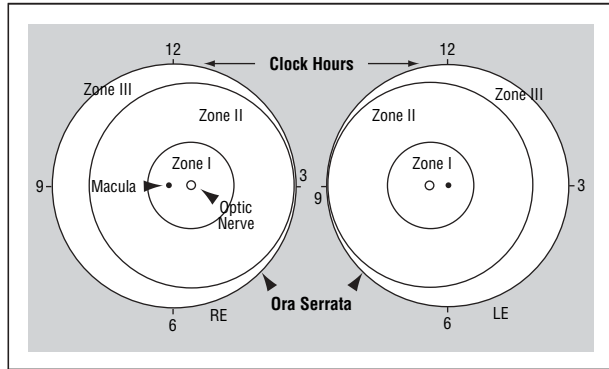


Figure 1. Scheme of retina of right eye (RE) and left eye (LE) showing zone borders and clock hours used to describe the location and extent of retinopathy of prematurity (adapted the Committee for the Classification of Retinopathy of Prematurity^{1(p131)}).

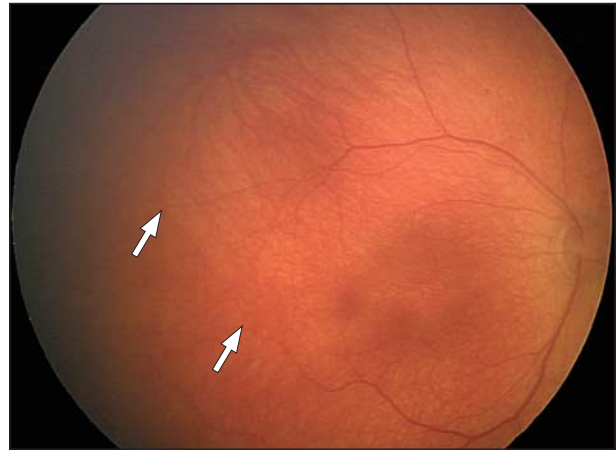


Figure 2. Fundus photograph to demonstrate immature retinal vascularization in the right eye. Note the progressive tapering of retinal vessels (arrows).

1. Concept of a more virulent retinopathy usually observed in the lowest-birth-weight infants—aggressive posterior ROP (AP-ROP).

2. Description of an intermediate level of vascular dilatation and tortuosity (pre-plus disease) between normal-appearing posterior pole vasculature and frank plus disease that has marked dilatation and tortuosity of the posterior pole vessels.

3. Clarification of the extent of zone I.

LOCATION OF DISEASE

For the purpose of defining the anteroposterior location of the retinopathy, 3 concentric zones of retinal involvement have been previously described¹ with the zone designation based on the findings at the time of examination (**Figure 1**). Each zone is centered on the optic disc rather than the macula, in contrast to standard retinal drawings. This convention was selected because normal retinal vasculature proceeds outward from the center of the optic disc toward the ora serrata in an orderly fashion, although it is recognized that the extent of retinal vascularization and ROP may be observed closer to the optic disc nasally than temporally based on the measurement from retinal photographs.³

Zone I (the innermost zone) consists of a circle (**Figure 1**), the radius of which extends from the center of the optic disc to twice the distance from the center of the optic disc to the center of the macula. The

retinal area defined as zone II extends centrifugally from the edge of zone I to the nasal ora serrata (at the 3-o'clock position in the right eye and the 9-o'clock position in the left eye). Zone III is the residual crescent of retina anterior to zone II. By convention, zones II and III are considered to be mutually exclusive. Retinopathy of prematurity should be considered to be in zone II until it can be determined with confidence that the nasal-most 2 clock hours are vascularized to the ora serrata.^{4,5}

As a practical approach for the clinician, the approximate temporal extent of zone I can be determined by using a 25- or 28-diopter (D)–condensing lens. By placing the nasal edge of the optic disc at one edge of the field of view, the limit of zone I is at the temporal field of view.⁶ Any ROP that is continuous and circumferential must by definition fall into 1 of these 2 posterior zones. Examiners must take care to be sure that the vessels, indeed, reach the ora serrata nasally and that there is not ROP in the 2 nasal-most sectors before re-categorizing the eye as a zone III eye; if this cannot be fully ascertained, the eye should still be considered a zone II eye.

EXTENT OF DISEASE

The extent of disease is recorded as hours of the clock or as 30° sectors.¹ As the observer looks at each eye, the 3-o'clock position is to the right and nasal in the right eye and temporal in the left eye, and the 9-o'clock position is to the left and

temporal in the right eye and nasal in the left eye (**Figure 1**). The boundaries between sectors lie on the clock hour positions; that is, the 12-o'clock sector extends from 12 o'clock to 1 o'clock.

STAGING THE DISEASE

Prior to the development of ROP in the premature infant, vascularization of the retina is incomplete or “immature” (**Figure 2**). There are 5 stages that are used to describe the abnormal vascular response at the junction of the vascularized and avascular retina. Because more than 1 ROP stage may be present in the same eye, staging for the eye as a whole is determined by the most severe manifestation present. However, for purposes of recording the complete examination, each stage is defined and the extent of each stage by clock hours or sector is recorded.

Stage 1: Demarcation Line

This line is a thin but definite structure that separates the avascular retina anteriorly from the vascularized retina posteriorly (**Figure 3**). There is abnormal branching or arcing of vessels leading up to the demarcation line that is relatively flat, white, and lies within the plane of the retina. Vascular changes can be apparent prior to the development of the demarcation line, such as dilatation rather than tapering of the peripheral retinal vessels, but these changes are insufficient for the diagnosis of ROP.

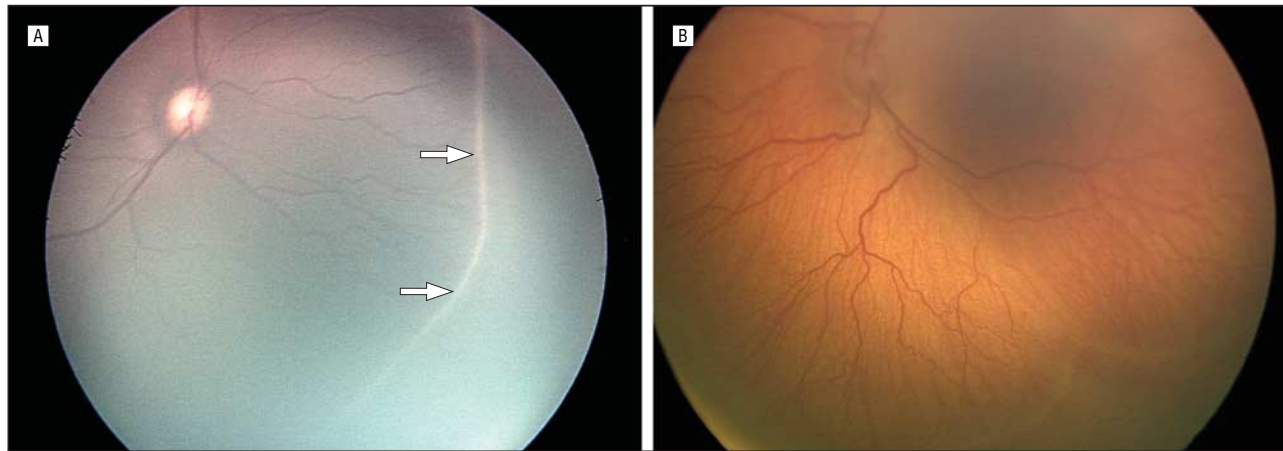


Figure 3. Fundus photograph to illustrate the demarcation line of stage 1. A, View of the demarcation line in stage 1 retinopathy of prematurity. B, Another example of the demarcation line seen in stage 1 retinopathy of prematurity (arrows) and absence of any retinopathy of prematurity.

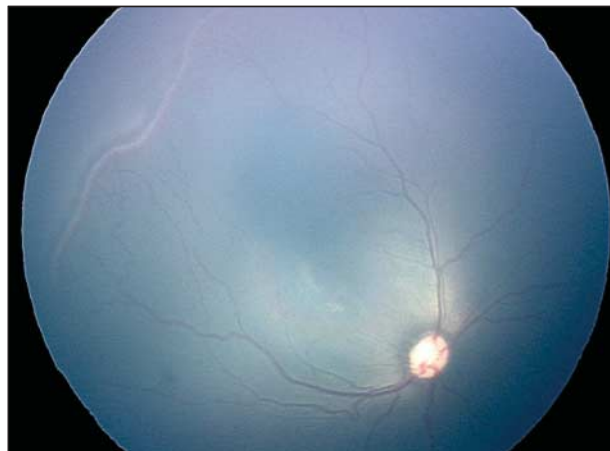

Figure 4. Pigmented fundus photograph showing stage 2 retinopathy of prematurity at the junction between vascularized and avascular retina.

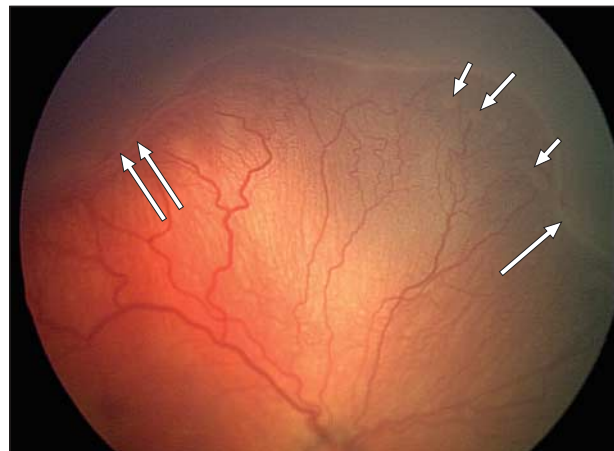


Figure 5. Fundus photograph showing the ridge between vascularized and avascular retina characteristic of stage 2 retinopathy of prematurity (single long arrow). Small isolated tufts of new vessels (popcorn) lie on the retinal surface (short arrows). Note also stage 3 retinopathy of prematurity is present in the left hand portion of the photograph (double long arrows).

Stage 2: Ridge

The ridge is the hallmark of stage 2 ROP (**Figure 4** and **Figure 5**). It arises in the region of the demarcation line, has height and width, and extends above the plane of the retina. The ridge may change from white to pink and vessels may leave the plane of the retina posterior to the ridge to enter it. Small isolated tufts of neovascular tissue lying on the surface of the retina, commonly called “popcorn” (**Figure 5**) may be seen posterior to this ridge structure. Such lesions do not constitute the degree of fibrovascular growth that is a necessary condition for stage 3.

Stage 3: Extraretinal Fibrovascular Proliferation

In stage 3, extraretinal fibrovascular proliferation or neovascularization

extends from the ridge into the vitreous (**Figure 6**). This extraretinal proliferating tissue is continuous with the posterior aspect of the ridge, causing a ragged appearance as the proliferation becomes more extensive. The severity of a stage 3 lesion can be subdivided into mild, moderate, or severe depending on the extent of extraretinal fibrovascular tissue infiltrating the vitreous.

Stage 4: Partial Retinal Detachment

Stage 4 is divided into extrafoveal (stage 4A) and foveal (stage 4B) partial retinal detachments (**Figure 7**). Stage 4 retinal detachments are generally concave and most are circumferentially oriented. The extent of retinal detachment depends on the number of clock hours of fibrovas-

cular traction and their degree of contraction. Typically, retinal detachments begin at the point of fibrovascular attachment to the vascularized retina. In progressive cases, the fibrous tissue continues to contract and the tractional retinal detachment increases in height, extending both anteriorly and posteriorly. Radial detachments and more complex configurations of retinal detachments are less common.

Stage 5: Total Retinal Detachment

Retinal detachments are generally tractional and may occasionally be exudative (**Figure 8**). They are usually funnel shaped. The configuration of the funnel itself permits a subdivision of this stage. The funnel is

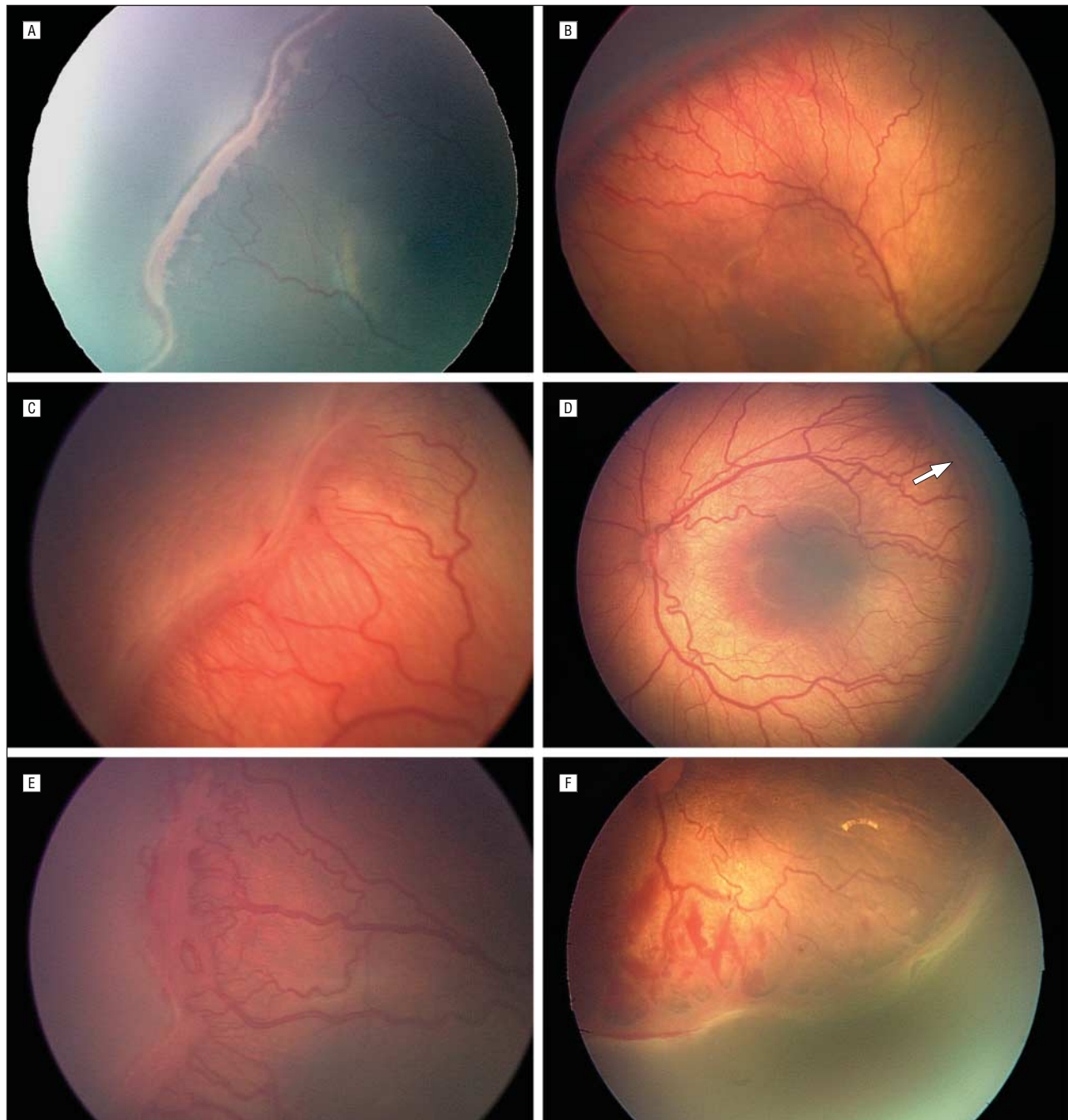


Figure 6. Fundus photographs of mild to severe stage 3 retinopathy of prematurity (ROP). A, View of mild stage 3 ROP. This represents progression of the ROP imaged in Figure 4. B, View of stage 3 moderate ROP with fingerlike extensions posterior to the ridge. Note that the posterior pole vessels show increased tortuosity and dilatation. C, View of moderate stage 3 ROP. D, View of moderate stage 3 ROP. Substantial amounts of extraretinal fibrovascular proliferation are seen infiltrating the vitreous posterior to the ridge. Note the tortuosity and dilatation of posterior pole vessels that are insufficient for plus disease. E, View of severe stage 3 ROP with massive infiltration of neovascular tissue surrounding the ridge. F, View of severe stage 3 ROP with infiltration of the vitreous with a dominantly fibrotic proliferation.

divided into anterior and posterior parts. When open both anteriorly and posteriorly, the detachment generally has a concave configuration and extends to the optic disc. A second frequent configuration is one in which the funnel is narrow in both its anterior and posterior aspects and the detached retina is located just behind the lens. A third, less common type, is one in which the fun-

nel is open anteriorly but narrowed posteriorly. Least common is a funnel that is narrow anteriorly and open posteriorly.

PLUS DISEASE

Along with the changes described earlier at the leading edge of the abnormally developing retinal vasculature, additional signs indicating the

severity of active ROP may occur. These include increased venous dilatation and arteriolar tortuosity of the posterior retinal vessels and may later increase in severity to include iris vascular engorgement, poor pupillary dilatation (rigid pupil), and vitreous haze. This important constellation of signs in the original classification was referred to as plus disease. (**Figure 9**) Subsequent mul-

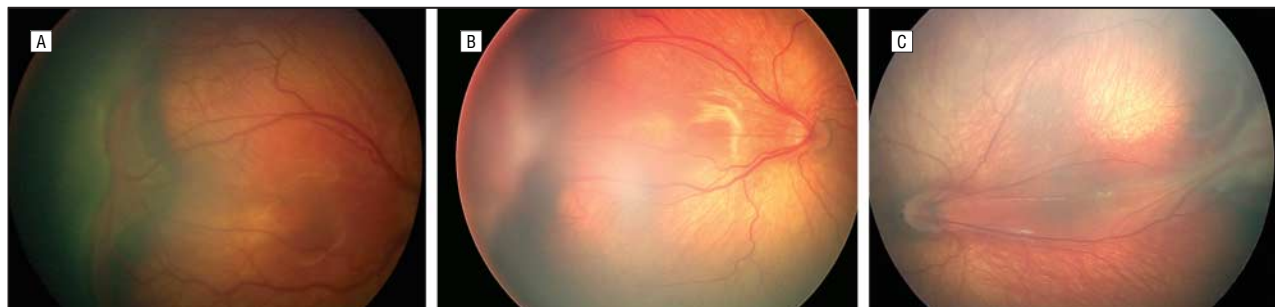

Figure 7. Examples of stages 4A and B retinopathy of prematurity. A, Example of stage 4A, extrafoveal partial retinal detachment. Note also the straightening of temporal vascular arcade. B, Fundus photograph of stage 4B, partial retinal detachment involving macula. Note absence of normal choroidal pattern in macular region. C, Fundus photograph showing stage 4B retinal detachment with extensive temporal dragging of vessels and macula.

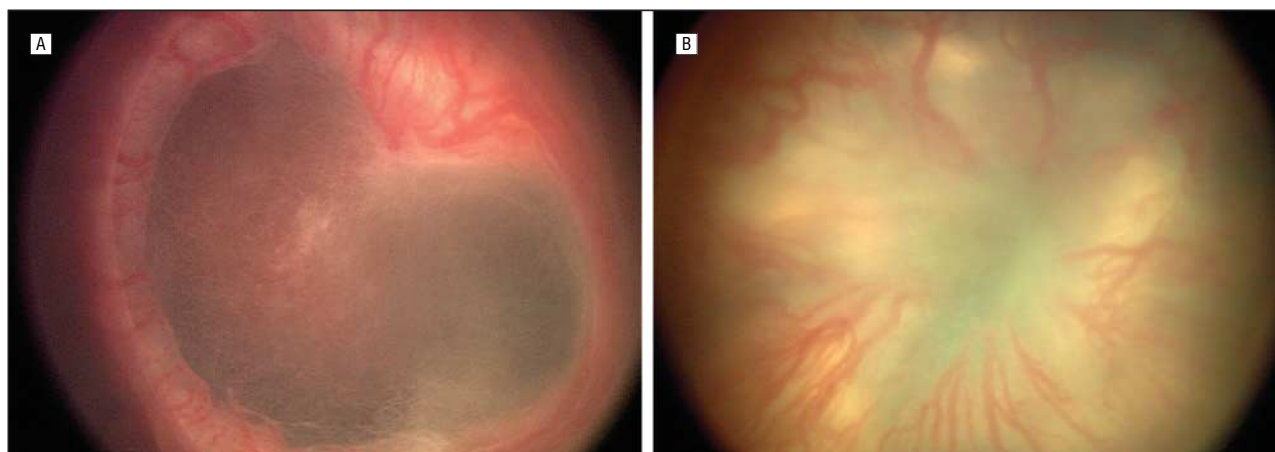


Figure 8. Fundus views of stage 5 retinopathy of prematurity. A, View of stage 5 retinopathy of prematurity, total retinal detachment with open funnel configuration. B, View of stage 5 funnel retinal detachment that is open anteriorly but narrowed posteriorly.

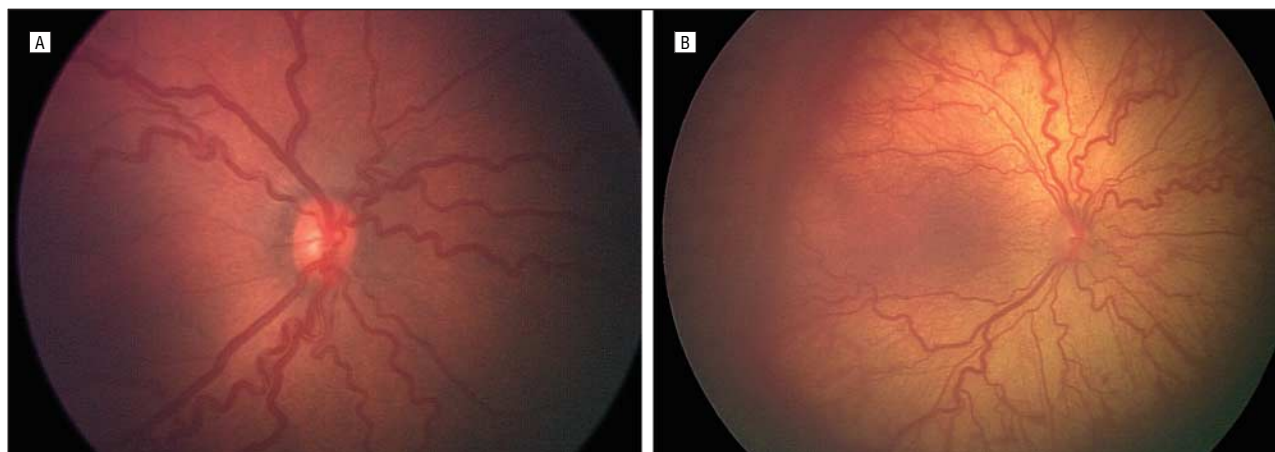


Figure 9. Two fundus photographs with example of plus disease. A, Another example of plus disease. B, View of retinopathy of prematurity with plus disease.

ticentered clinical trials have used a “standard” photograph (**Figure 10**) to define the minimum amount of vascular dilatation and tortuosity required to make the diagnosis of plus disease.^{4,7-9} This definition has been further refined in the later clinical trials in which the diagnosis of plus disease could be made if sufficient vascular dilatation and tortuosity are present in at least 2 quadrants of the

eye.⁷ A + symbol is added to the ROP stage number to designate the presence of plus disease. For example, stage 2 ROP combined with posterior vascular dilatation and tortuosity would be written “stage 2+ ROP.”

PRE-PLUS DISEASE

There is a spectrum of ROP activity indicated by abnormal dilatation and

tortuosity of the posterior pole vessels. Plus disease is the severe form of this vascular abnormality. This report defines pre-plus disease as vascular abnormalities of the posterior pole that are insufficient for the diagnosis of plus disease but that demonstrate more arterial tortuosity and more venous dilatation than normal. Over time, the vessel abnormalities of pre-plus may progress to frank

plus disease as the vessels dilate and become more tortuous (**Figure 11**). The presence of pre-plus disease can be noted beside the stage, for example, stage 2 with pre-plus disease.

AGGRESSIVE POSTERIOR ROP

An uncommon, rapidly progressing, severe form of ROP is designated AP-ROP. If untreated, it usually progresses to stage 5 ROP. The characteristic features of this type of ROP are its posterior location, prominence of plus disease, and the ill-defined nature of the retinopa-

thy (**Figure 12A**). This rapidly progressing retinopathy has been referred previously as “type II ROP” and “Rush disease,”¹⁰⁻¹² but was not specifically included in ICROP.² Aggressive, posterior ROP seems to be the most appropriate term since the diagnosis can be made on a single visit and it does not require evaluation over time.

Aggressive posterior retinopathy of prematurity is observed most commonly in zone I, but may also occur in posterior zone II. Early in the development of AP-ROP, the posterior pole vessels show in-

creased dilation and tortuosity in all 4 quadrants that is out of proportion to the peripheral retinopathy. These vascular changes progress rapidly. Shunting occurs from vessel to vessel within retina and not solely at the junction between vascular and avascular retina.¹³ As a result, in AP-ROP it is often difficult to distinguish between arterioles and venules because of the significant dilation and tortuosity of both vessel types. There may also be hemorrhages at the junction between the vascularized and avascular retina.

Another important feature of AP-ROP is that it usually does not progress through the classic stages 1 to 3.¹⁴ (Figure 12B) Aggressive posterior retinopathy of prematurity may appear as only a flat network of neovascularization at the deceptively featureless junction between vascularized and nonvascularized retina and may be easily overlooked by a less experienced observer (Figure 12A and B). Aggressive posterior retinopathy of prematurity typically extends circumferentially and is often accompanied by a circumferential vessel (Figure 12C). Performing indirect ophthalmoscopy with a 20-D condensing lens instead of a 25-

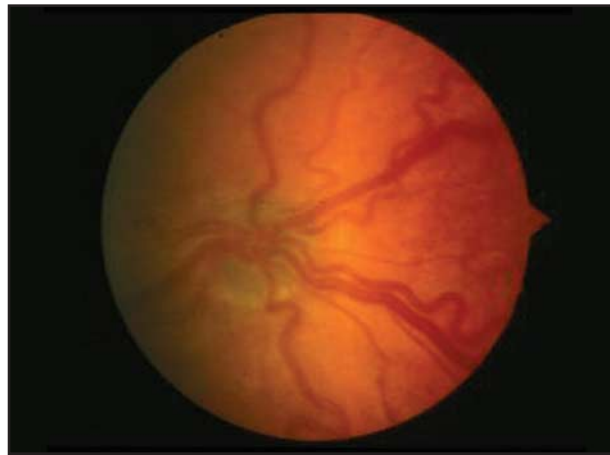


Figure 10. Fundus photograph of posterior venous dilatation and arteriolar tortuosity characteristic of plus disease (standard photograph defining plus disease reproduced with permission from original International Committee for the Retinopathy of Prematurity').

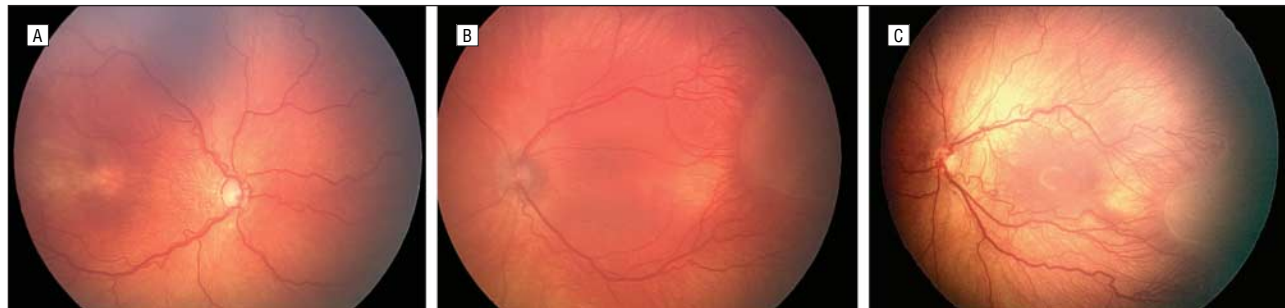


Figure 11. Examples of pre-plus disease. A, Pre-plus disease with greater tortuosity of posterior pole vessels than normal but insufficient to be designated plus disease. B, Another example of pre-plus disease. C, Pre-plus disease with insufficient dilatation and tortuosity of vessels to be designated plus disease. Stage 2 retinopathy of prematurity is present temporally in this image.

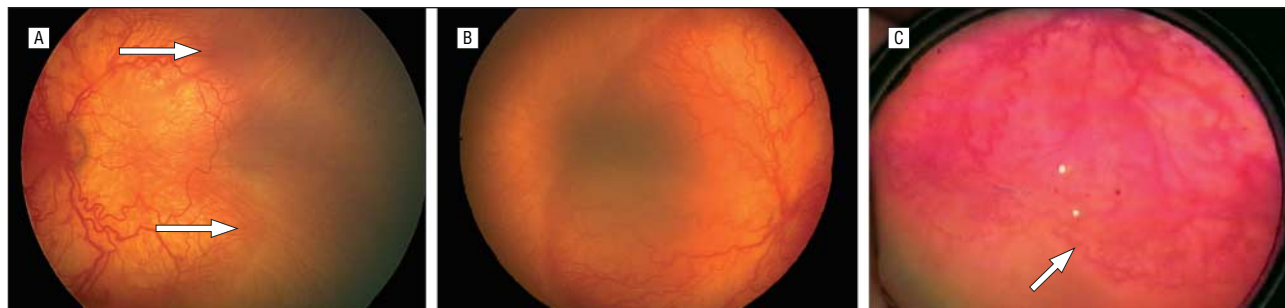


Figure 12. Examples of aggressive posterior retinopathy of prematurity (AP-ROP). A, View of AP-ROP. Note posterior location, prominence of plus disease, and modest-appearing proliferative retinopathy (arrows). B, Fundus photograph of AP-ROP demonstrating plus disease associated with brushlike neovascular proliferation at junction between vascular and avascular retina. This example of AP-ROP occurs in zone I. C, A further example of AP-ROP. Note circumferential vessel at edge of vascularized retina (reproduced with permission from Katz et al¹⁰).

Australia: Glen A. Gole, MD, FRANZCO; Canada: Anna L. Ells, MD, FRCSC (Co-Chair); Chile: Ximena Katz, MD; Sweden: Gerd Holmstrom, MD, PhD; United Kingdom: Alistair R. Fielder, FRCOphth; United States: Antonio Capone, Jr, MD; John T. Flynn, MD; William G. Good, MD; Jonathan M. Holmes, BM, BCh; J. Arch McNamara, MD; Earl A. Palmer, MD; Graham E. Quinn, MD, MSCE (Co-Chair); Michael J. Shapiro, MD; Michael G. J. Trese, MD; David K. Wallace, MD.

Table. Involutional Sequelae of Retinopathy of Prematurity*

- I. Peripheral changes
 - A. Vascular
 1. Failure of peripheral retinal vascularization
 2. Abnormal, nondichotomous branching of the retinal vessels
 3. Vascular arcades with circumferential interconnection
 4. Telangiectatic vessels
 - B. Retinal
 1. Pigmentary changes
 2. Vitreoretinal interface changes
 3. Thin retina
 4. Peripheral folds
 5. Vitreous membranes with or without attachment to retina
 6. Lattice-like degeneration
 7. Retinal breaks
 8. Traction-rhegmatogenous retinal detachment
- II. Posterior changes
 - A. Vascular
 1. Vascular tortuosity
 2. Straightening of blood vessels in temporal arcade
 3. Decrease in angle of insertion of major temporal arcade
 - B. Retinal
 1. Pigmentary changes
 2. Distortion and ectopia of macula
 3. Stretching and folding of retina in macular region leading to periphery
 4. Vitreoretinal interface changes
 5. Vitreous membrane
 6. Dragging of retina over optic disc
 7. Traction-rhegmatogenous retinal detachment

*Reproduced with permission from the International Committee for the Retinopathy of Prematurity.²

or 28-D lens may help to distinguish the deceptively featureless neovascularization.

REGRESSION OF ROP

Most ROP regresses spontaneously by a process of involution or evolution from a vasoproliferative phase to a fibrotic phase. One of the first signs of stabilization of the acute phase of ROP is failure of the reti-

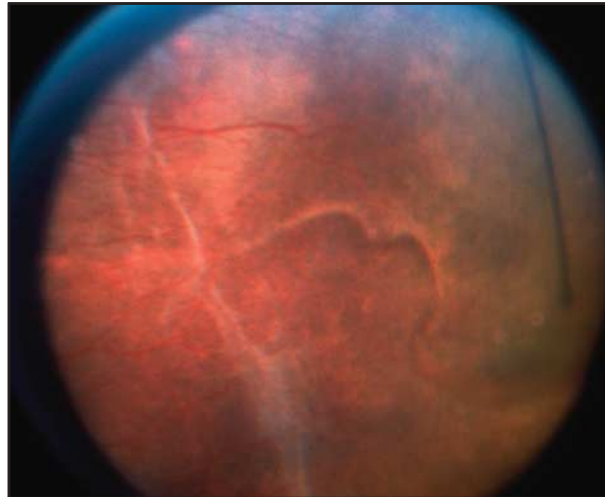


Figure 13. Peripheral fundus photograph showing a scarcity of retinal vessels and area of avascular retina anterior to the equator with regressed retinopathy of prematurity (reproduced with permission from the International Committee for the Retinopathy of Prematurity²).

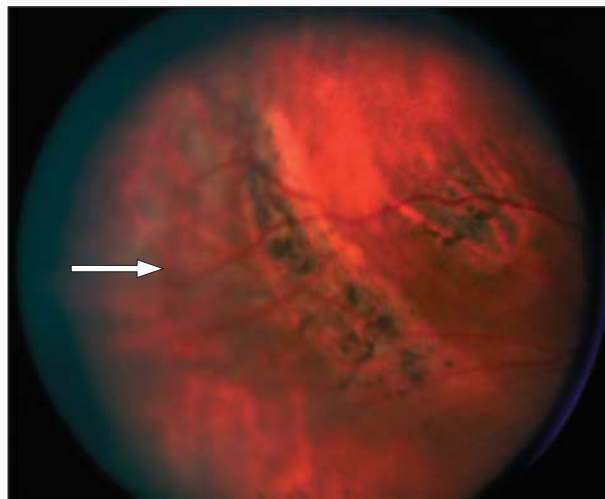


Figure 14. Abnormal vessel formation in periphery with vascular arcades and shunt vessels (arrow) in the region of regressed retinopathy of prematurity (reproduced with permission from the International Committee for the Retinopathy of Prematurity²).

nopathy to progress to the next stage.¹⁵ Certain morphological signs characterize the onset of regression or involution. The process of regression occurs largely at the junction of vascular and avascular retina as retinal vascularization advances peripherally. On serial examinations, the anteroposterior location of retinopathy may change from zone I to zone II or from zone II to zone III. The ridge may change in color from salmon pink to white.

Involutional sequelae include a broad spectrum of peripheral and posterior retinal and vascular changes

that are listed in the **Table**. The more severe the acute phase of the retinopathy, the more likely involutional changes will be severe as the disease enters what was formerly termed the “cicatrical” phase.¹⁶ During the process of involution, conspicuous features are vascular abnormalities such as prominent areas of retinal avascularity (**Figure 13**), abnormal branching of vessels with formation of arcades (**Figure 14**), and telangiectatic vessels. Pigmentary changes may be subtle but more often become large areas of decreased or even increased pigmentation lo-

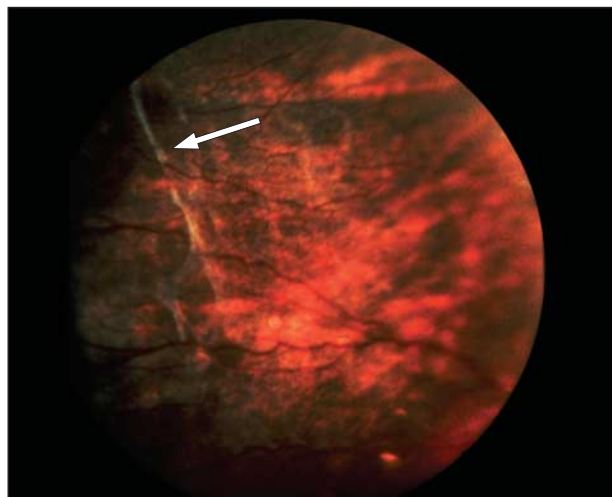


Figure 15. Retinovitreal interface changes (arrow) in the fundus that take the form of delicate lines in an area of previously active retinopathy of prematurity (reproduced with permission from the International Committee for the Retinopathy of Prematurity²).

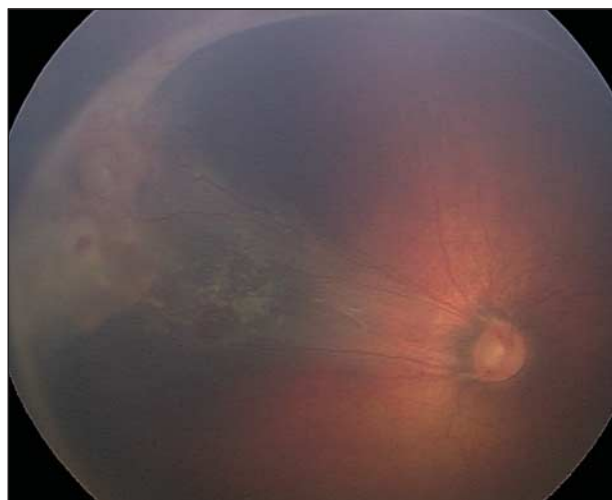


Figure 16. Fundus photograph of severe macular heterotopia with marked peripheral fibrosis.

cated along blood vessels and in underlying retinal pigment epithelium, as seen through an avascular retina. Circumferential retinovitreal interface changes may be seen as delicate lines (**Figure 15**) or more prominent ridges. In general, the more severe the peripheral changes, the more severe the posterior pole changes. These are tractional phenomena that can vary from minor distortions of foveal architecture to severe displacements of major retinal vessels, usually temporally and often accompanied by dragging of the retina over the optic disc (macular heterotopia or ectopia) (**Figure 16**). Finally, traction and rhegmatogenous retinal detachment and, rarely, exudative detachment can develop as late complications of regressed ROP.

CONCLUSIONS

As stated in the original classification, “the unifying principle under-

lying this classification is the following: the more posterior the disease and the greater the amount of involved retinal vascular tissue, the more serious the disease.”^{1(p1133)} This statement was made based on expert opinion, without an extensive supporting database; however, over the last 20 years many large studies have provided substantial support for this statement.³⁻⁹ The current report is in response to increased understanding of this disorder that resulted from research that occurred in large part owing to the structure that the original classification provided. More detailed classification of the scarring later phases of the retinopathy awaits further analysis.

Retinopathy of prematurity is a complex disease that requires careful description so that treatment can be delivered at the most appropriate time. The purpose of this document is to provide the medical community caring for the infants at risk for

development of ROP with a method of describing the condition in detail that will optimize management and enable the findings to be discussed among parents and caregivers.

Submitted for Publication: May 17, 2004; accepted October 11, 2004.

Correspondence: Graham E. Quinn, MD, MSCE, Pediatric Ophthalmology, First Floor, Wood Building, The Children’s Hospital of Philadelphia, Philadelphia, PA 19104 (quinn@email.chop.edu).

Funding/Support: The committee members gratefully acknowledge the support of the following agencies that made our work possible: The Alberta Children’s Hospital Foundation, Calgary; The Eye Foundation-Calgary; Department of Surgery, Faculty of Medicine, University of Calgary; Massie Research Laboratories Inc, Pleasanton, Calif; and Bausch & Lomb Canada Inc, Markham, Ontario.

Acknowledgment: We acknowledge the retinal photographs contributed by Leslie MacKeen, BSc; Anna Ells, MD, FRCSC; Alistair Fielder, FRCOphth; and Ximena Katz, MD.

REFERENCES

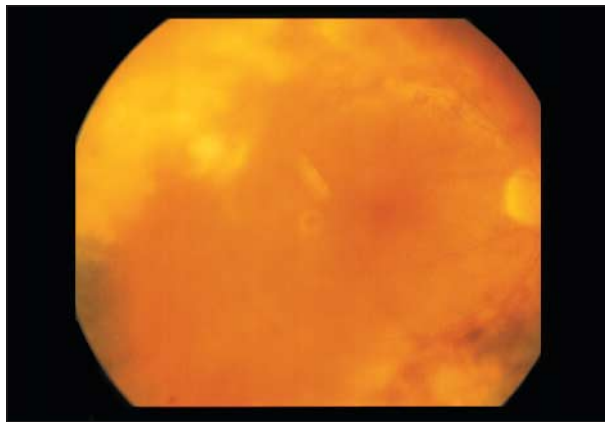
1. Committee for the Classification of Retinopathy of Prematurity. An International Classification of Retinopathy of Prematurity. *Arch Ophthalmol.* 1984;102:1130-1134.
2. ICROP Committee for Classification of Late Stages ROP. An international classification of retinopathy of prematurity, II: the classification of retinal detachment. *Arch Ophthalmol.* 1987;105:906-912.
3. Gallagher K, Moseley M, Tandon A, Watson MP, Cocker KD, Fielder AR. Asymmetric location of retinopathy of prematurity in the nasal and temporal retina. *Arch Ophthalmol.* 2003;121:1563-1568.
4. Cryotherapy for Retinopathy of Prematurity Cooperative Group. The natural ocular outcome of premature birth and retinopathy. *Arch Ophthalmol.* 1994;112:903-912.
5. Palmer E, Flynn J, Hardy R, et al. Incidence and early course of retinopathy of prematurity. *Ophthalmology.* 1991;98:1628-1638.
6. Vander J, Handa J, McNamara A, et al. Early Treatment of posterior retinopathy of prematurity: a controlled trial. *Ophthalmology.* 1997;104:1731-1736.
7. The STOP-ROP Multicenter Study Group. Supplemental therapeutic oxygen for prethreshold retinopathy of prematurity (STOP-ROP): a randomized, controlled trial, I: primary outcomes. *Pediatrics.* 2000;105:295-310.
8. The design of the multicenter study of light reduction in retinopathy of prematurity (LIGHT-ROP). *J Pediatr Ophthalmol Strabismus.* 1999;36:257-263.

9. Early Treatment for Retinopathy of Prematurity Cooperative Group. Revised indications for the treatment of retinopathy of prematurity: results of the Early Treatment for Retinopathy of Prematurity Randomized Trial. *Arch Ophthalmol.* 2003;121:1684-1694.
10. Soejima N, Takagi I, Takashima Y. Clinical studies on retinopathy of prematurity, severe and rapidly progressive type. *Folia Ophthalmol Jpn.* 1976; 27:155-161.
11. Morizane H. Initial sign and clinical course of the most severe form of acute proliferative retrolental fibroplasia (type II) [in Japanese]. *Nippon Ganka Gakkai Zasshi.* 1976;80:54-61.
12. Uemura Y, Tsukahara I, Nagata M, et al. Diagnostic and therapeutic criteria for retinopathy of prematurity. *Committee's Report Appointed by the Japanese Ministry of Health and Welfare.* Tokyo, Japan: Japanese Ministry of Health and Welfare; 1974.
13. Kushner B, Essner D, Cohen I, Flynn J. Retrolental fibroplasia, II: pathologic correlation. *Arch Ophthalmol.* 1977;95:29-38.
14. Katz X, Kychenthal A, Dorta P. Zone I retinopathy of prematurity. *J AAPOS.* 2000;4:373-376.
15. Repka MX, Palmer EA, Tung B; on behalf of the CRYO-ROP Cooperative Group. Involvement of retinopathy of prematurity. *Arch Ophthalmol.* 2000; 118:645-649.
16. A classification of retrolental fibroplasia. *Am J Ophthalmol.* 1953;36:1333-1335.

ARCHIVES Web Quiz Winner

March 2005 Web Quiz Winner

Congratulations to the winner of our March quiz, Paolo Antonio S. Silva, MD, Sentro Oftalmologico Jose Rizal, Department of Ophthalmology and Visual Sciences, University of the Philippines–Philippine General Hospital, Manila, the Philippines. The correct answer to our March challenge was cytomegalovirus retinitis. For a complete discussion of this case, see the Clinicopathologic Reports, Case Reports, and Small Case Series section in the April Archives (Stewart MW, Bolling JP, Mendez JC. Cytomegalovirus retinitis in an immunocompetent patient. *Arch Ophthalmol.* 2005;123:572-574).



Be sure to visit the *Archives of Ophthalmology* Web site (<http://www.archophthalmol.com>) and try your hand at our Clinical Challenge Interactive Quiz. We invite visitors to make a diagnosis based on selected information from a case report or other feature scheduled to be published in the following month's print edition of the ARCHIVES. The first visitor to e-mail our Web editors with the correct answer will be recognized in the print journal and on our Web site and will also be able to choose one of the following books published by AMA Press: *Clinical Eye Atlas*, *Clinical Retina*, or *Users' Guides to the Medical Literature*.